



Diagnostic efficacy of tract-specific diffusion tensor imaging in cervical spondylotic myelopathy with electrophysiological examination validation

Yanming Fang¹ and Sisi Li²

¹ Spine Department, Beijing Jishuitan Hospital, Capital Medical University, Beijing, China

² Center for Biomedical Imaging Research, Tsinghua University, Beijing, China
ymfang@pku.edu.cn, realrarefang@gmail.com

Abstract

Purpose: This study aimed to investigate the effectiveness of tract-specific diffusion tensor imaging (DTI) metrics in identifying the responsible segments for neurological dysfunction in cervical spondylotic myelopathy (CSM).

Methods: The study encompassed nineteen patients in CSM group and ten healthy caregivers in control group. All participants underwent a comprehensive physical examination, MRI assessment, and DTI examination conducted by a senior chief physician. Intraoperative spinal cord electrophysiological examination was performed as the objective measure of spinal cord function during surgery for patients. MRI parameters including the aspect ratio, transverse ratio, T2 hyperintensities of the spinal cord and DTI metrics parameters such as axial diffusivity (AD), mean diffusivity (MD), radial diffusivity (RD), fractional anisotropy (FA) for both whole spinal cord column and dorsal column were collected. Receiver operating characteristic curves were constructed to evaluate the diagnostic efficacy of the parameters. The area under the curve (AUC), sensitivity, and specificity were calculated.

Results: The AUC of DTI (Dorsal column) parameters was larger than the corresponding parameters of the DTI (Whole spinal cord). AD of DTI-Dorsal Column possessed the greatest efficacy (AUC=0.823, sensitivity=84.21%, specificity=77.32%) to determine the responsible segment, larger than AD of DTI-Whole spinal cord, aspect ratio and transverse ratio. Diagnostic efficacy of DTI and MRI parameters was influenced by cervical spine segment.

Conclusions: AD from the DTI-Dorsal Column exhibited the most significant potential in identifying responsible segments. The diagnostic effectiveness of both DTI and MRI parameters was notably influenced by the specific cervical spine segment.

1 Introduction

Identifying specific segments responsible for neurological dysfunction is complex, especially in cases with multi-stage compression. While invasive spinal cord electrophysiological assessments have been proposed, non-invasive methods for precisely identifying neurological function at distinct spinal cord segments are currently unavailable. DTI offers indirect insights into neurological function through metrics like AD, MD, RD and FA (Mori & Zhang, 2006; Sasiadek et al., 2012; Song et al., 2011). Previous research highlights DTI's significance in diagnosing CSM, but its ability in pinpointing the exact cervical compression segment responsible for neurological dysfunction is limited. Our study aims to validate the diagnostic efficacy of DTI metrics (AD, MD, RD, and FA) in identifying the specific segment responsible for neurological dysfunction in CSM. By using electrophysiology as the gold standard, we aim to improve neurofunctional assessment accuracy beyond the limitations of the mJOA scale (Bednarik et al., 2008; Valošek et al., 2021; Wen et al., 2014).

2 Methods

The study encompassed nineteen participants diagnosed with CSM, including 10 males and 9 females. Additionally, a control group consisting of ten healthy caregivers (5 males and 5 females) were recruited with no symptoms and no compressions on MRI. All participants underwent a comprehensive physical examination, MRI assessment, and DTI examination conducted by a senior chief physician. Intraoperative spinal cord electrophysiological examination was performed as the objective measure of spinal cord function during surgery for patients. Several parameters were collected from the MR images, including the aspect ratio (defined as the anteroposterior diameter / the transverse diameter of the corresponding segment's spinal cord), transverse ratio (defined as the transverse diameter of the corresponding segment's spinal cord / the transverse diameter of the spinal cord at C2/3), and T2 hyperintensities of the spinal cord. Furthermore, quantitative DTI metrics, such as AD, MD, RD, FA were calculated using automatic region-of-interest analysis for both whole spinal cord column and dorsal column. Receiver operating characteristic curves were constructed to evaluate the diagnostic efficacy of the aspect ratio, transverse ratio, and DTI parameters. The AUC, sensitivity, and specificity were calculated.

3 Results

As determined by electrophysiological examination, neurological dysfunction was found in 2 patients due to C3/4 compression, in 10 patients due to C4/5 compression, in 6 patients due to C5/6 compression, and in 1 patient due to C6/7 compression. The modified Japanese Orthopedic Association scale (mJOA) was 12.71 ± 1.55 in the CSM group, with 4.87 ± 0.72 for sensory nerve function and 5.05 ± 1.35 for motor nerve function. For the control group, none of the volunteers had neurological dysfunction. T2 high signal was found at the most stenotic segment in 14 patients of the CSM group. Considering all the cervical segments, the aspect ratio (AUC=0.823) is more capable of determining the responsible segment than transverse ratio (AUC=0.661). AD, MD, and RD were significantly higher while FA was significantly lower in the responsible segment than in the irresponsible segment ($P < 0.05$). The AUC of DTI (Dorsal column) parameters was larger than the corresponding parameters of the DTI (Whole spinal cord). AD of DTI-Dorsal Column possessed the greatest efficacy (AUC=0.823) to determine the responsible segment, larger than AD of DTI-Whole spinal cord, aspect ratio and transverse ratio. Subgroup analysis revealed that the diagnostic efficacy of DTI and MRI parameters was influenced by cervical spine segment.

4 Discussion

Not all compressed segments contribute to the observed neurological dysfunction (Tanaka et al., 2005). Few studies computed the AUC to assess the efficacy of DTI in diagnosing CSM. Several studies assessed the diagnostic performance of DTI met for CSM by reporting sensitivity and specificity. Wang's study reported a sensitivity of 30.77% and specificity of 91.89% for the FA to identify myelopathic segments in CSM (Wang et al., 2015). Our results were much better in some ways (DTI-dorsal column, sensitivity=73.68%, specificity=69.07%). In addition, our study involved the utilization of the Spinal Cord Toolbox (SCT) to partition the nerve conduction tracts of the spinal cord. We found that the dorsal tract exhibited superior diagnostic performance to the whole spinal cord. This finding is in line with the results of a study conducted by Jan Valošek et al. (Valošek et al., 2021). This might be related to the use of SSEP which was generated from the dorsal sensory functional area as an evaluation function index in our electrophysiological studies. The discrepancies observed between our study and other existing research may be attributed to the use of different standards for assessing spinal cord function. While previous DTI studies primarily relied on the mJOA score as the standard for evaluating spinal cord function (Shen et al., 2018). Our study employed intraoperative neurophysiological monitoring as an invasive examination method to detect a more accurate neurological function (Suetomi et al., 2016).

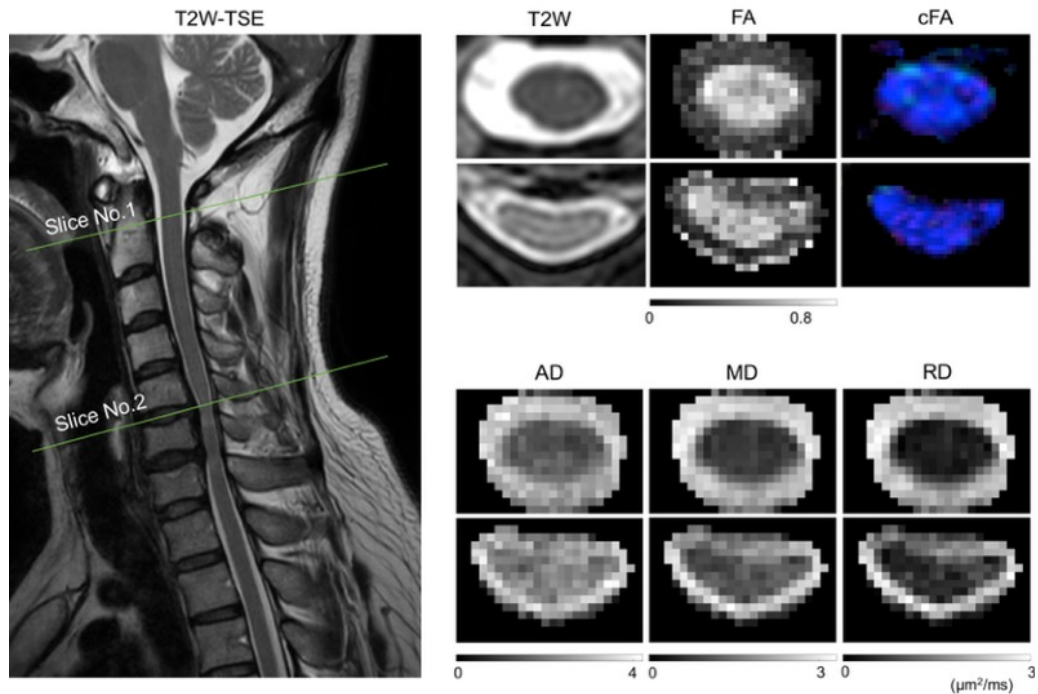


Figure 1 The T2W anatomical MR image along with calculated DTI metrics and color encoded FA maps (cFA) for a non-compressed slice (Slice No. 1) and a compressed slice (Slice No. 2).

Examination methods		AUC	P	Sensitivity%	Specificity%
Physical examination	Sensory nerve dysfunction			26.32	86.60
	Motor nerve dysfunction			36.84	92.78
	The most stenotic segment			57.89	91.75
MRI	T2 high signals			52.63	90.72
	Aspect ratio	0.823	0.001	68.42	82.47
	Transverse ratio	0.661	0.027	68.42	67.01
DTI (Whole spinal cord)	AD	0.822	0.001	89.47	77.32
	MD	0.806	0.001	78.95	76.29
	RD	0.783	0.001	89.47	60.82
	FA	0.750	0.001	84.21	54.64
DTI (Dorsal Column)	AD	0.823	0.001	84.21	77.32
	MD	0.816	0.001	89.47	71.13
	RD	0.791	0.001	89.47	58.76
	FA	0.772	0.001	73.68	69.07

Table 1 Summary of Diagnostic efficacy MRI and DTI for the responsible segment. AD: Axial Diffusivity. MD: Mean Diffusivity. RD: Radial Diffusivity. FA: Fractional Anisotropy. AUC: Area under the curve. P: P-value of the AUC. Youden index: Sensitivity + Specificity – 1.

References

- Bednarik, J., Kadanka, Z., Dusek, L., Kerkovsky, M., Vohanka, S., Novotny, O., Urbanek, I., & Kratochvilova, D. (2008). Presymptomatic spondylotic cervical myelopathy: an updated predictive model. *European Spine Journal*, 17(3), 421-431. <https://doi.org/10.1007/s00586-008-0585-1>
- Mori, S., & Zhang, J. (2006). Principles of Diffusion Tensor Imaging and Its Applications to Basic Neuroscience Research. *Neuron*, 51(5), 527-539. <https://doi.org/https://doi.org/10.1016/j.neuron.2006.08.012>
- Sasiadek, M. J., Szewczyk, P., & Bladowska, J. (2012). Application of diffusion tensor imaging (DTI) in pathological changes of the spinal cord. *Med Sci Monit*, 18(6), Ra73-79. <https://doi.org/10.12659/msm.882891>
- Shen, C., Xu, H., Xu, B., Zhang, X., Li, X., Yang, Q., & Ma, X. (2018). Value of conventional MRI and diffusion tensor imaging parameters in predicting surgical outcome in patients with degenerative cervical myelopathy. *J Back Musculoskelet Rehabil*, 31(3), 525-532. <https://doi.org/10.3233/bmr-170972>
- Song, T., Chen, W.-J., Yang, B., Zhao, H.-P., Huang, J.-W., Cai, M.-J., Dong, T.-F., & Li, T.-S. (2011). Diffusion tensor imaging in the cervical spinal cord. *European Spine Journal*, 20(3), 422-428. <https://doi.org/10.1007/s00586-010-1587-3>
- Suetomi, Y., Kanchiku, T., Nishijima, S., Imajo, Y., Suzuki, H., Yoshida, Y., Nishida, N., & Taguchi, T. (2016). Application of diffusion tensor imaging for the diagnosis of segmental level of dysfunction in cervical spondylotic myelopathy. *Spinal Cord*, 54(5), 390-395. <https://doi.org/10.1038/sc.2015.192>

Tanaka, N., Fujimoto, Y., Yasunaga, Y., & Ochi, M. (2005). Functional diagnosis using multimodal spinal cord evoked potentials in cervical myelopathy. *J Orthop Sci*, 10(1), 3-7. <https://doi.org/10.1007/s00776-004-0859-3>

Valošek, J., Labounek, R., Horák, T., Horáková, M., Bednařík, P., Keřkovský, M., Kočica, J., Rohan, T., Lenglet, C., Cohen-Adad, J., Hlušík, P., Vlčková, E., Kadaňka, Z., Jr., Bednařík, J., & Svatkova, A. (2021). Diffusion magnetic resonance imaging reveals tract-specific microstructural correlates of electrophysiological impairments in non-myelopathic and myelopathic spinal cord compression. *Eur J Neurol*, 28(11), 3784-3797. <https://doi.org/10.1111/ene.15027>

Wang, S. Q., Li, X., Cui, J. L., Li, H. X., Luk, K. D., & Hu, Y. (2015). Prediction of myelopathic level in cervical spondylotic myelopathy using diffusion tensor imaging. *Journal of Magnetic Resonance Imaging*, 41(6), 1682-1688.

Wen, C.-Y., Cui, J.-L., Mak, K.-C., Luk, K. D. K., & Hu, Y. (2014). Diffusion tensor imaging of somatosensory tract in cervical spondylotic myelopathy and its link with electrophysiological evaluation. *The Spine Journal*, 14(8), 1493-1500. <https://doi.org/https://doi.org/10.1016/j.spinee.2013.08.052>